



PRESENTING CLINICAL SIGNS

DATE History: Grade II sternal murmur. Pre-anesthetic evaluation (dental).

ECHOCARDIOGRAPHIC FINDINGS

9/1/22 2D, M-mode, and Doppler study.

PERFORMED BY:

Dr. Meredith Swart

Left atrial size is normal. The mitral valve appears normal. Left ventricular wall thickness is normal. Left ventricular internal dimensions are normal. Left ventricular systolic function is hyperdynamic. The aorta and aortic valve are normal. Right atrial and right ventricular dimensions are normal. The tricuspid valve appears normal. The pulmonary artery and pulmonic valve are normal. No shunting lesions are visualized. No heartworms are visualized. No pericardial effusion or cardiac masses are seen.

INTERPRETED BY

Keith Blass, DVM,
MS, DACVIM
(Cardiology)

IVSd - 4.8 mm
LVPWd - 4.9 mm
LVIDd - 13.8 mm
LVIDs - 6.2 mm
FS - 55%

PATIENT

Shikoo Hubert

LVOT - 0.73 m/s
RVOT - 1.08 m/s

ASSESSMENT/RECOMMENDATIONS

SPECIES Normal echocardiogram

Feline

This examination demonstrates no evidence of structural heart disease. While a definitive reason for Shikoo's murmur was not identified, it's likely that his murmur is functional/innocent in nature, as no flow abnormalities that could result in the development of a pathologic murmur were appreciated in the image set.

BREED

Maine Coon Mix

No therapy is recommended based on this exam, nor are there any contraindications to general anesthesia or the use of any anesthetic drugs.

SEX

A recheck echocardiogram is recommended if the characteristics of Shikoo's murmur change, or if other new physical exam and/or clinical abnormalities suggestive of cardiac dysfunction develop.

MN

AGE

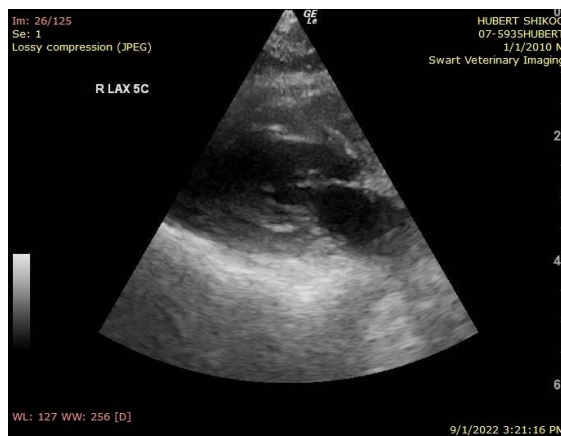
12 y

WEIGHT

10.3 lb

HOSPITAL NAME

Swart Veterinary
Imaging



The information and recommendations provided are based on the images presented by the referring veterinarian. No evaluation can be communicated regarding pathology that was not visible in the image/video clips provided.

REFERRING VET

Dr. Swart



DATE

Thank you for this referral. If the clinical or image interpretation does not parallel your findings or if I can be of any further assistance please contact me.

9/1/22

PERFORMED BY:

Keith Blass, DVM, MS, DACVIM (Cardiology)

KeithBlass@gmail.com

631-804-5754

Dr. Meredith Swart

INTERPRETED BY

Keith Blass, DVM,
MS, DACVIM
(Cardiology)

PATIENT

Shikoo Hubert

SPECIES

Feline

BREED

Maine Coon Mix

SEX

MN

AGE

12 y

WEIGHT

10.3 lb

HOSPITAL NAME

Swart Veterinary
Imaging

REFERRING VET

Dr. Swart